

Antral Opacities

Antral (Sinonasal) Radiopacities

- Sinusitis
- Hyperplastic Polyps
- Mucormycosis
- Papillomas
- Antral Carcinoma
- Sinonasal Undifferentiated Carcinoma
- Sarcomas

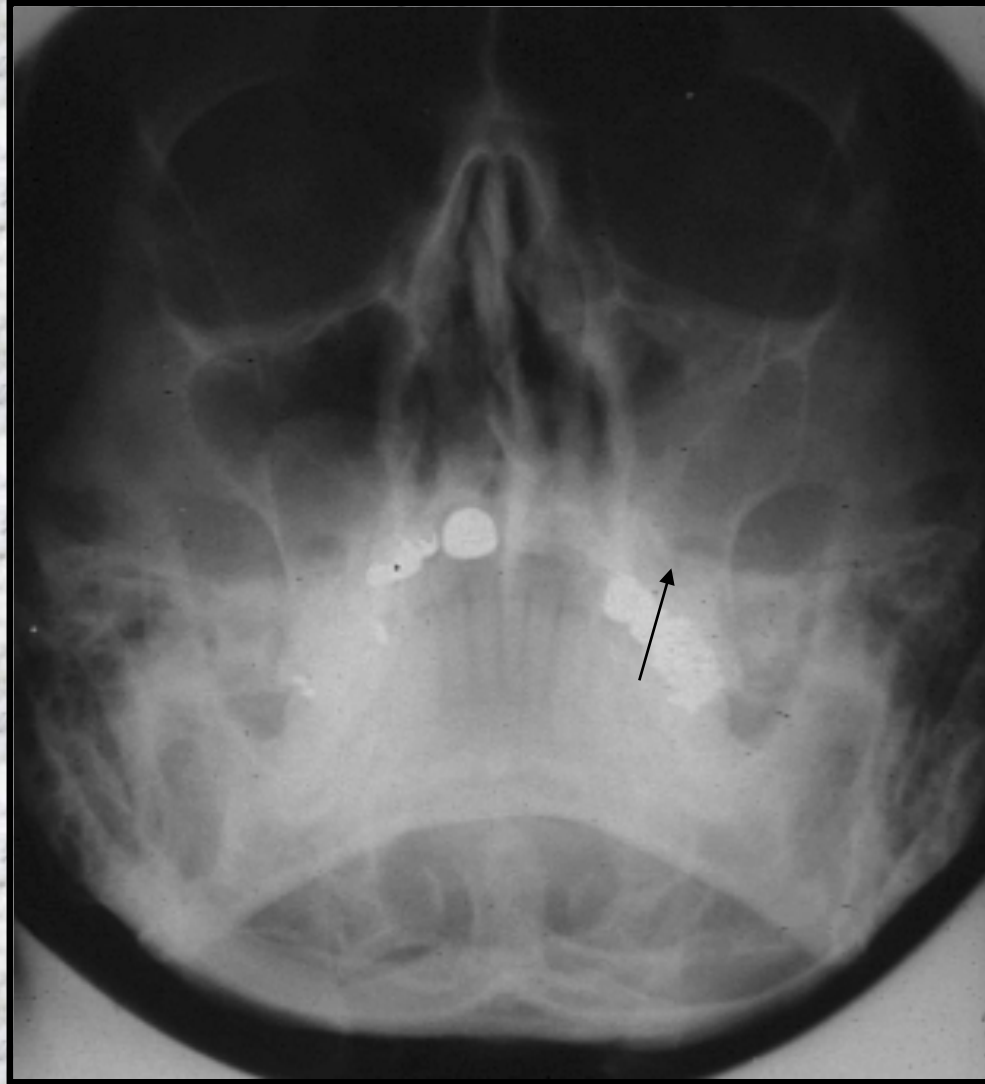
Sinusitis

- Infectious (Bacterial, Viral)
- Allergic Sinusitis
- Allergic Fungal Sinusitis

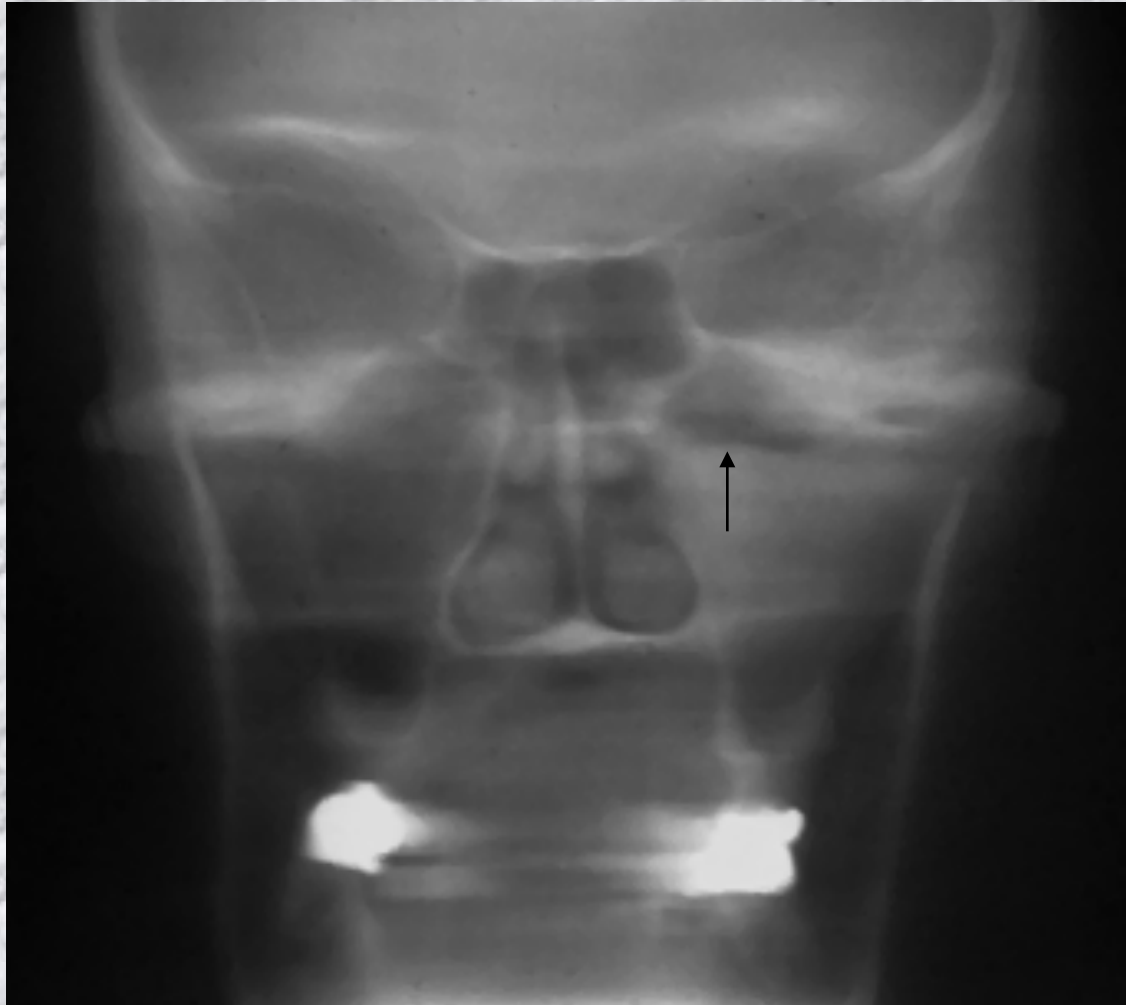
Bacterial Viral Sinusitis

- Streptococci
- A variety of URI viruses
- Acute Pain and Pressure
- Antral Opacity
 - Clouding
 - Air Fluid Level
- Antibiotics for Streptococcal Disease

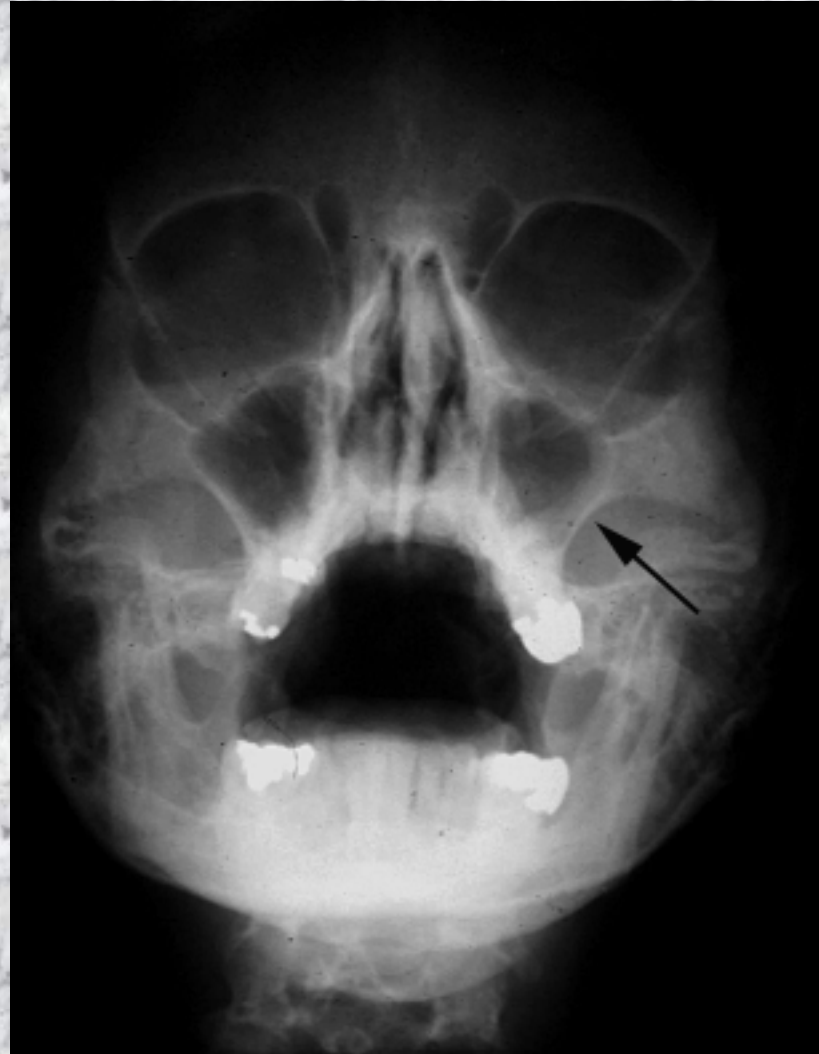
Sinusitis, Clouded Antrum



Sinusitis, Air/Fluid Level



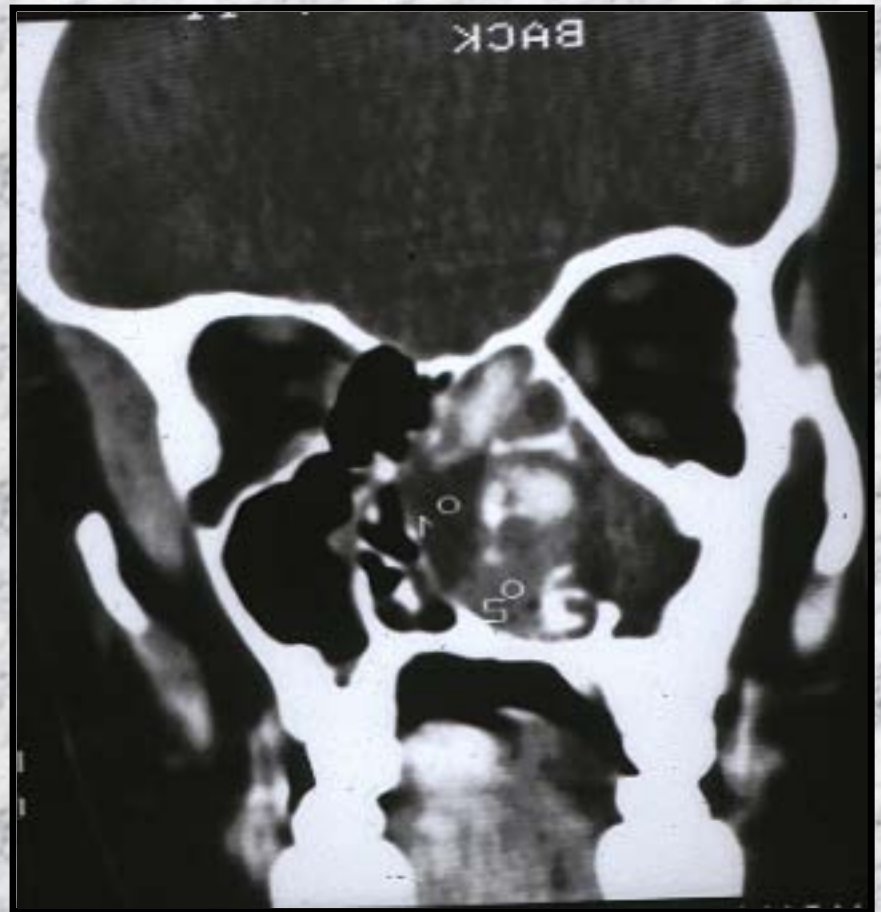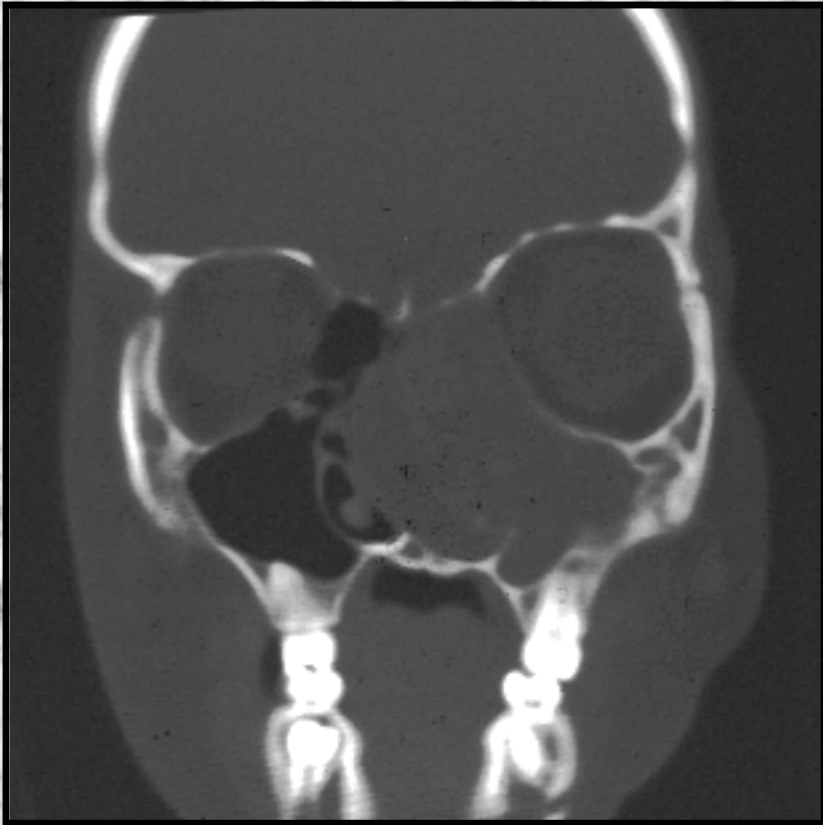
Chronic, Allergic Sinusitis Hyperplastic



Allergic Fungal Sinusitis

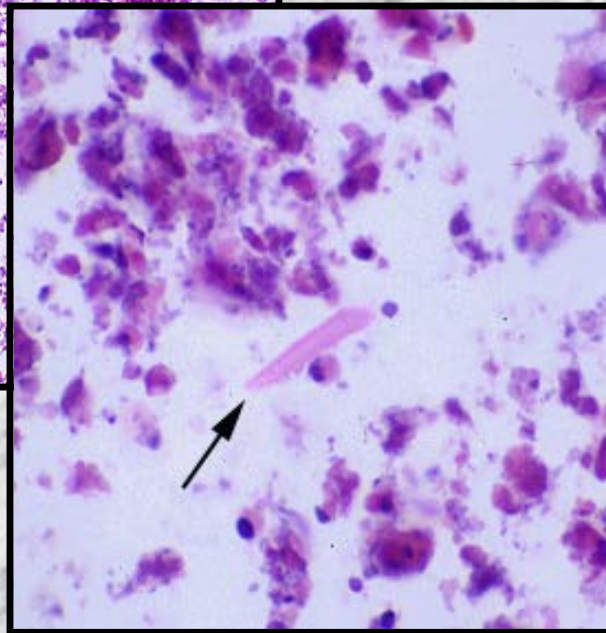
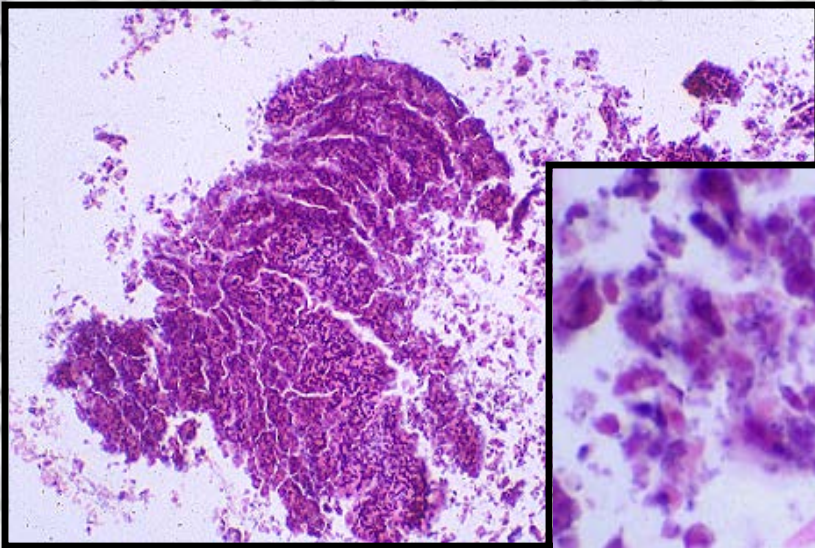
- Bipolaris Fungi are noninvasive yet antigenic
- Extensive expansion and osseous erosion
- Histology
 - Smudge eosinophils and necrosis
 - Charcot Leyden crystals
 - Large pleomorphic hyphae
- Treatment: Systemic Prednisone

Allergic Fungal Sinusitis

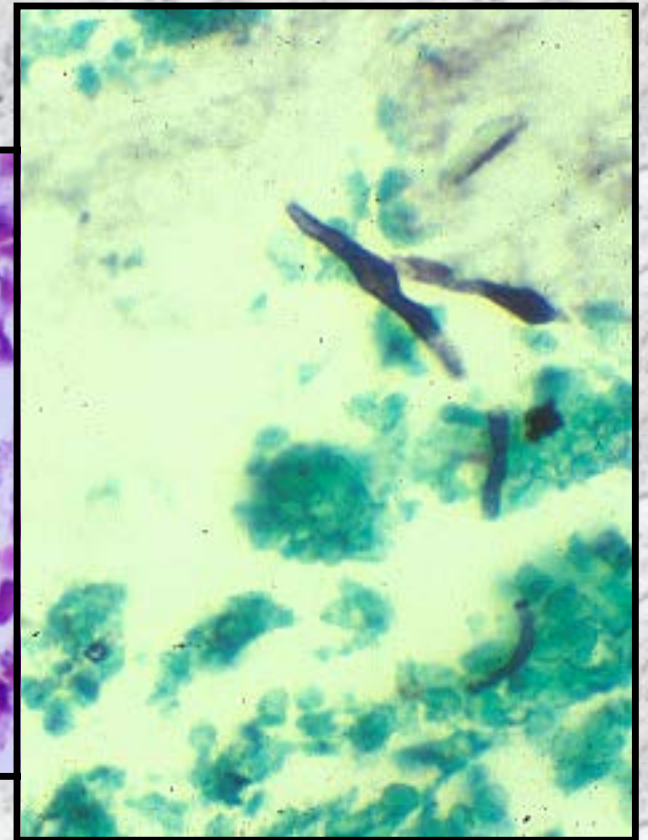


Allergic Fungal Sinusitis

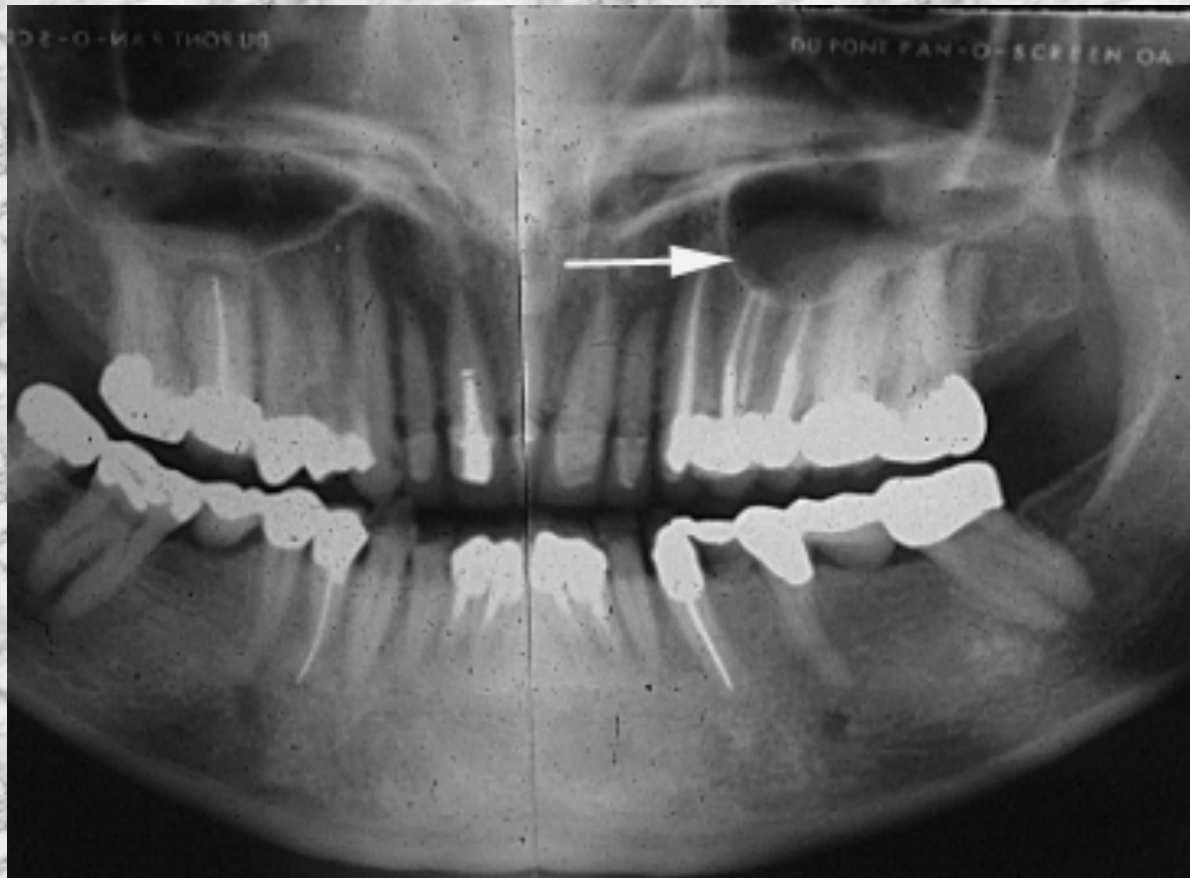
- Histology



- Bipolaris Fungi



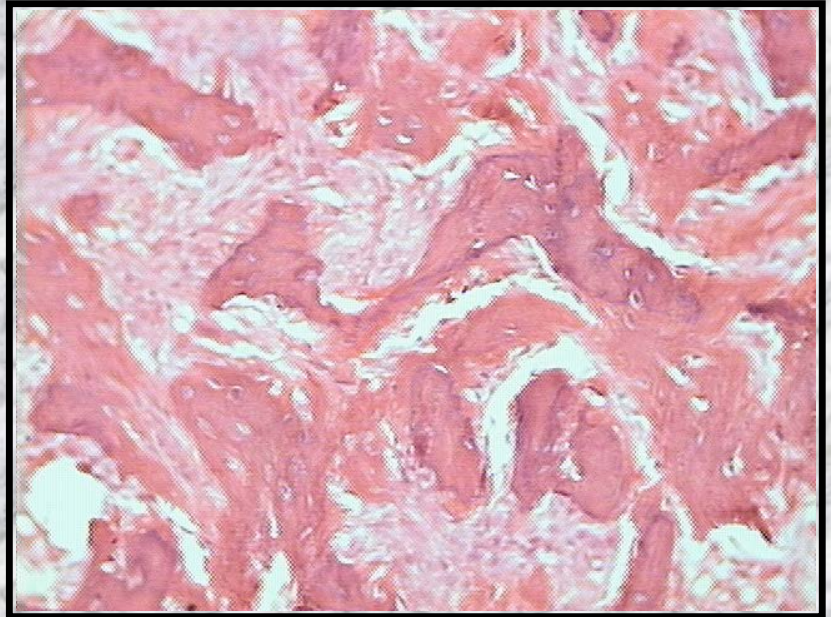
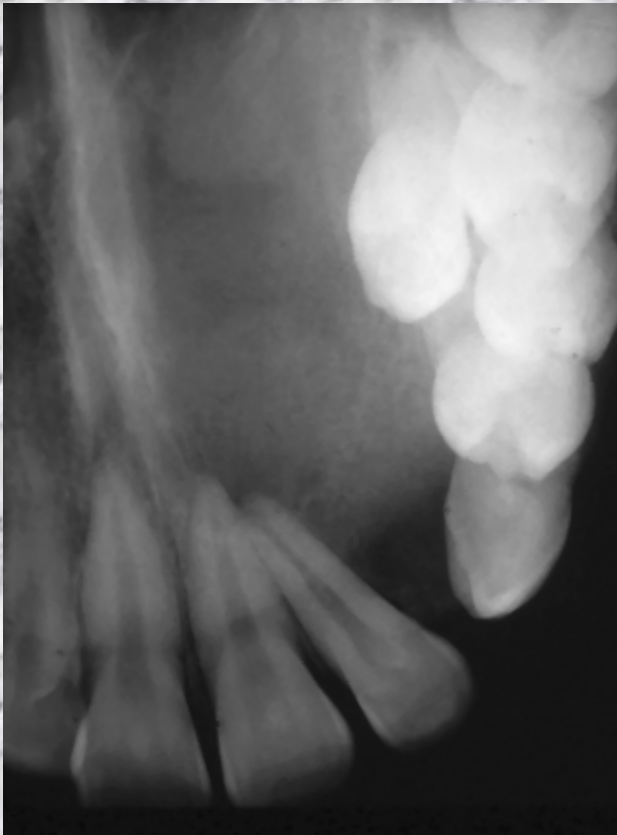
Hyperplastic Polyps



Fibrous Dysplasia

- Maxillary Bone expansion into the sinus
- Ground glass diffuse, nonmarginated expansile lesion
- Children and Teens
- Usually self limited, yet can be quite aggressive
- Tx: surgical sculpting

Fibrous dysplasia

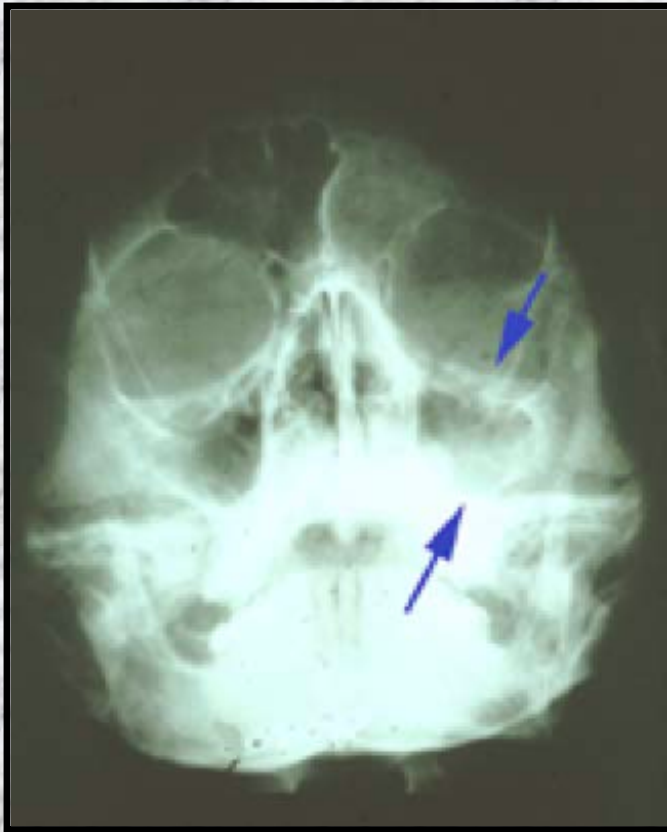

Mucormycosis

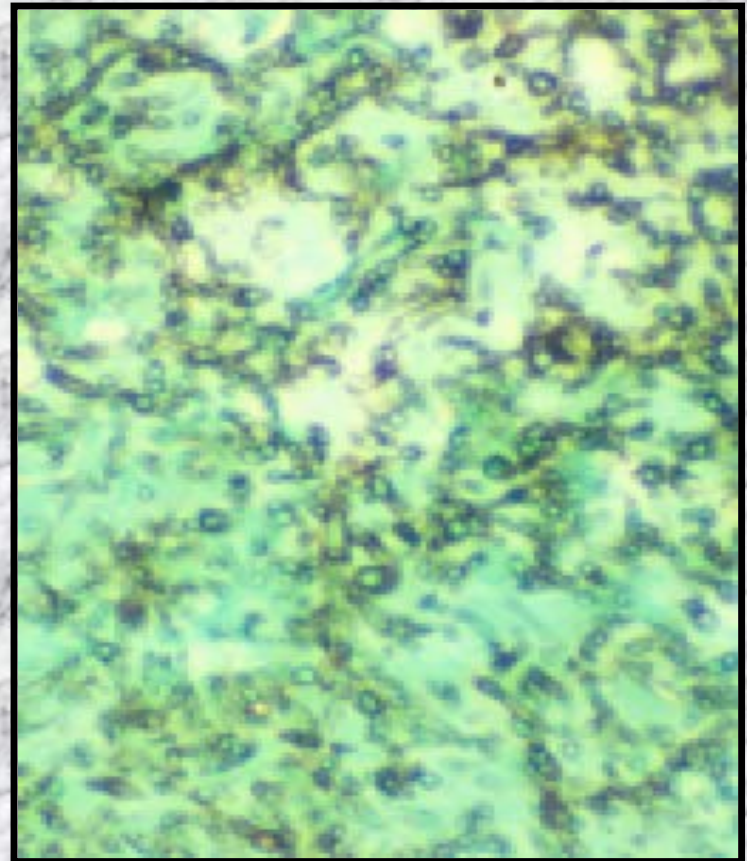
- Phycomycosis
- Debilitated patients
- Fungal entry into vascular lumens
- Widespread osseous necrosis of maxilla
- Affects other bones

Mucormycosis

- Radiograph



- Fungal organisms



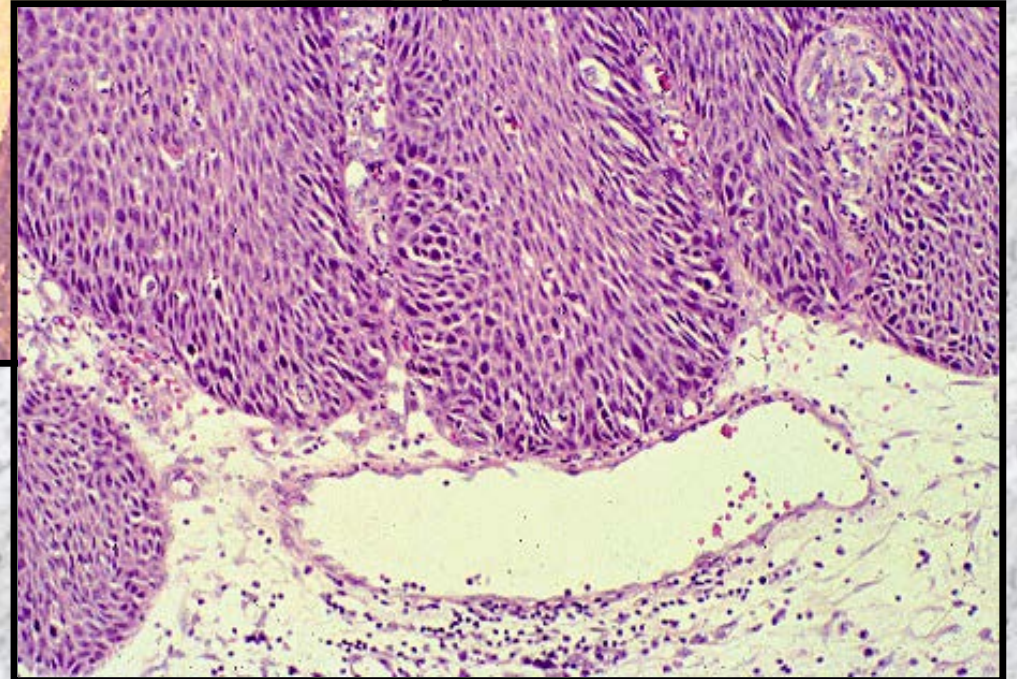
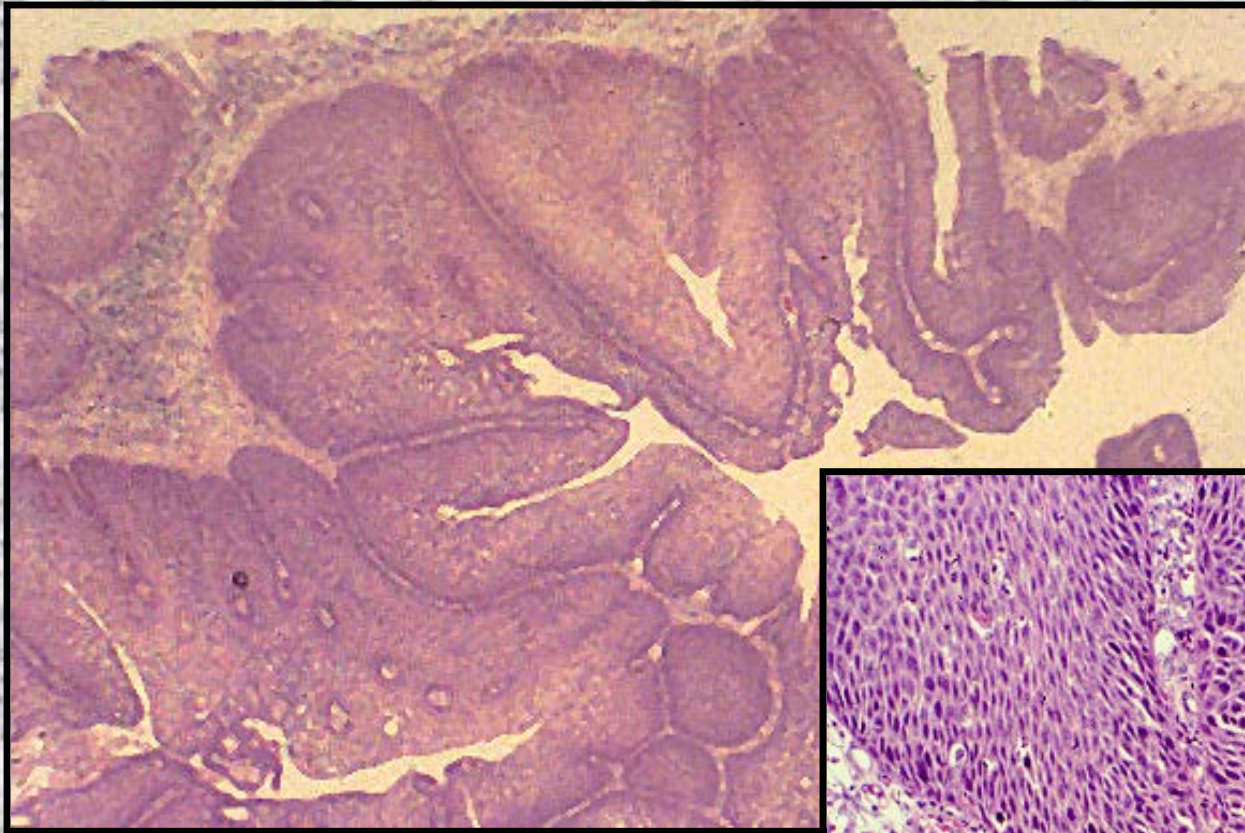
Sinonasal Papillomas

- Fungiform - Nasal Septum
- Inverted Papilloma -
Lateral Wall/Antrum
- Cylindric Cell Papilloma -
Lateral Wall

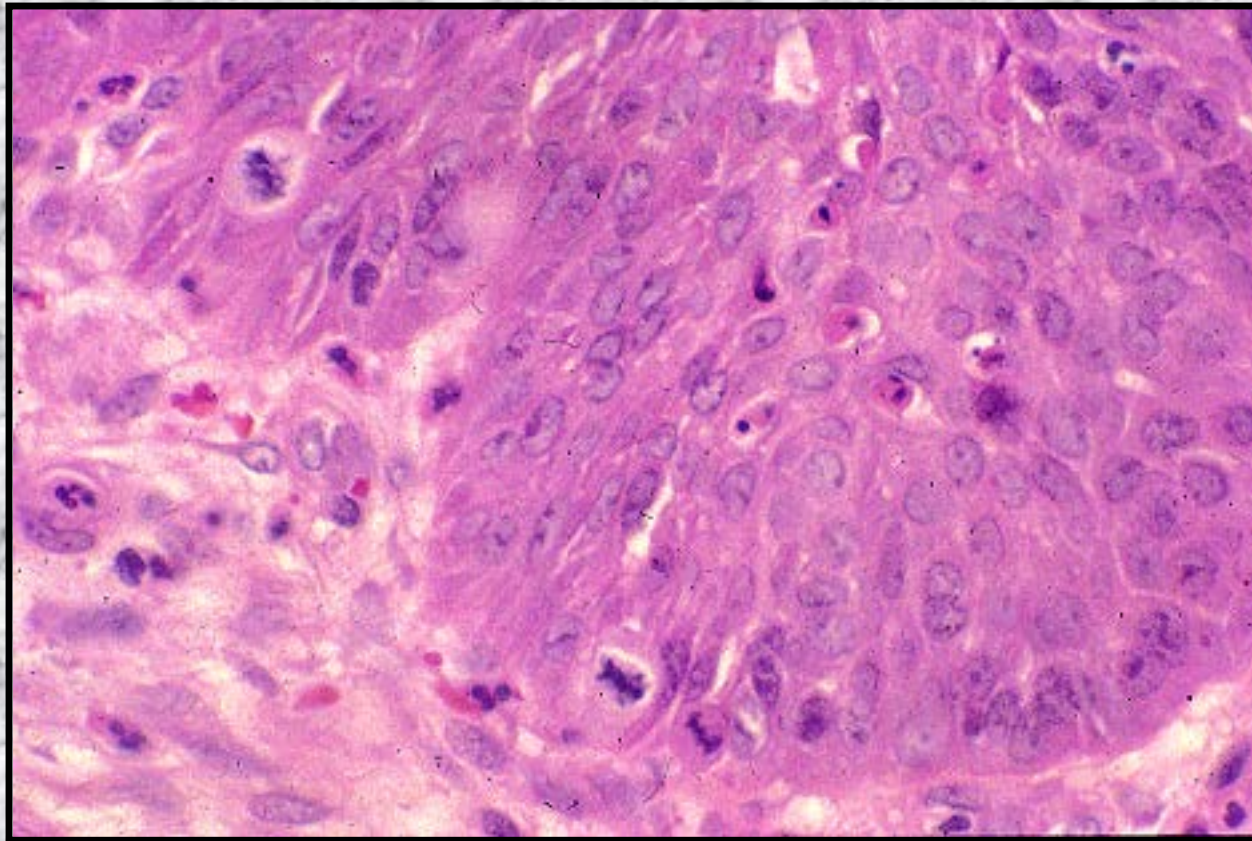
Inverted Papilloma

- Lateral Wall and Antrum
- Aggressive, osseous destructive
- 6% progress to squamous carcinoma

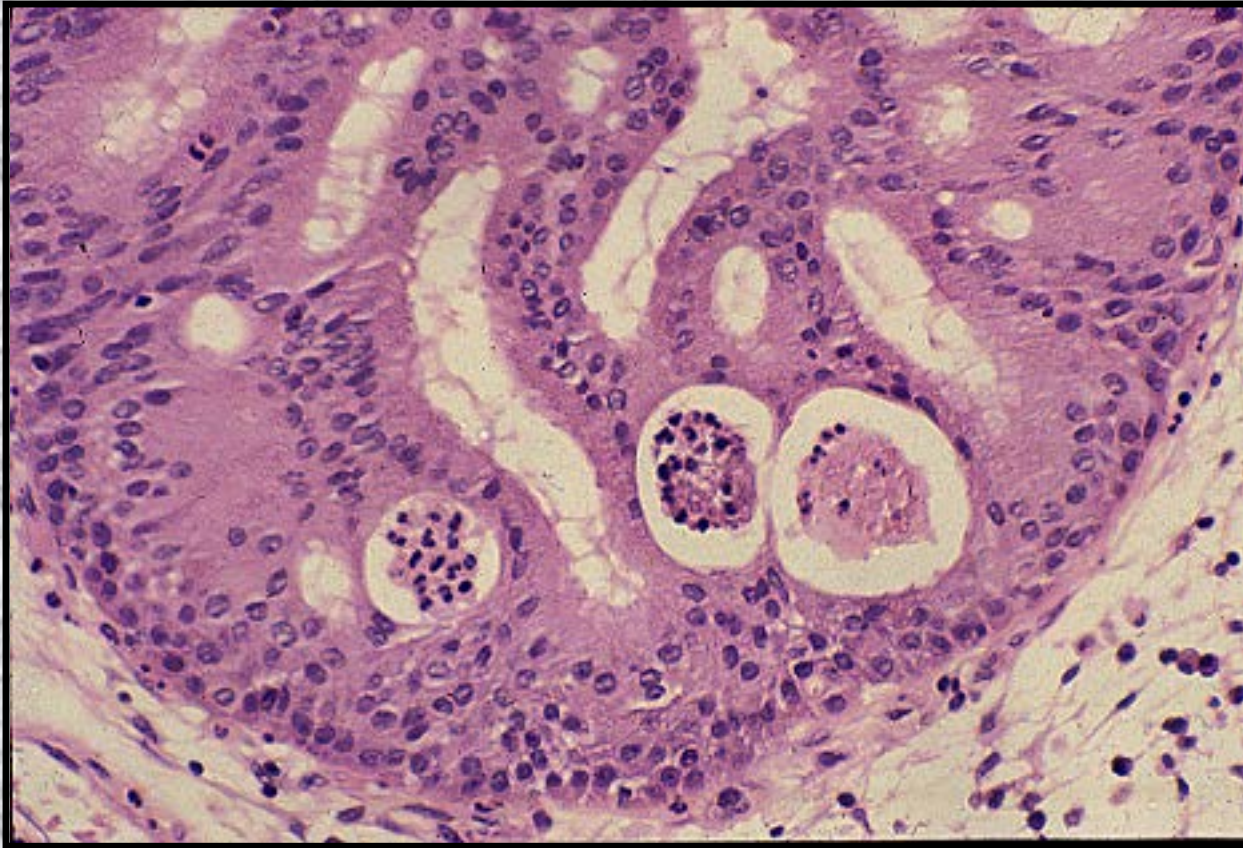
Inverted Papilloma



Inverted Papilloma with Dysplasia



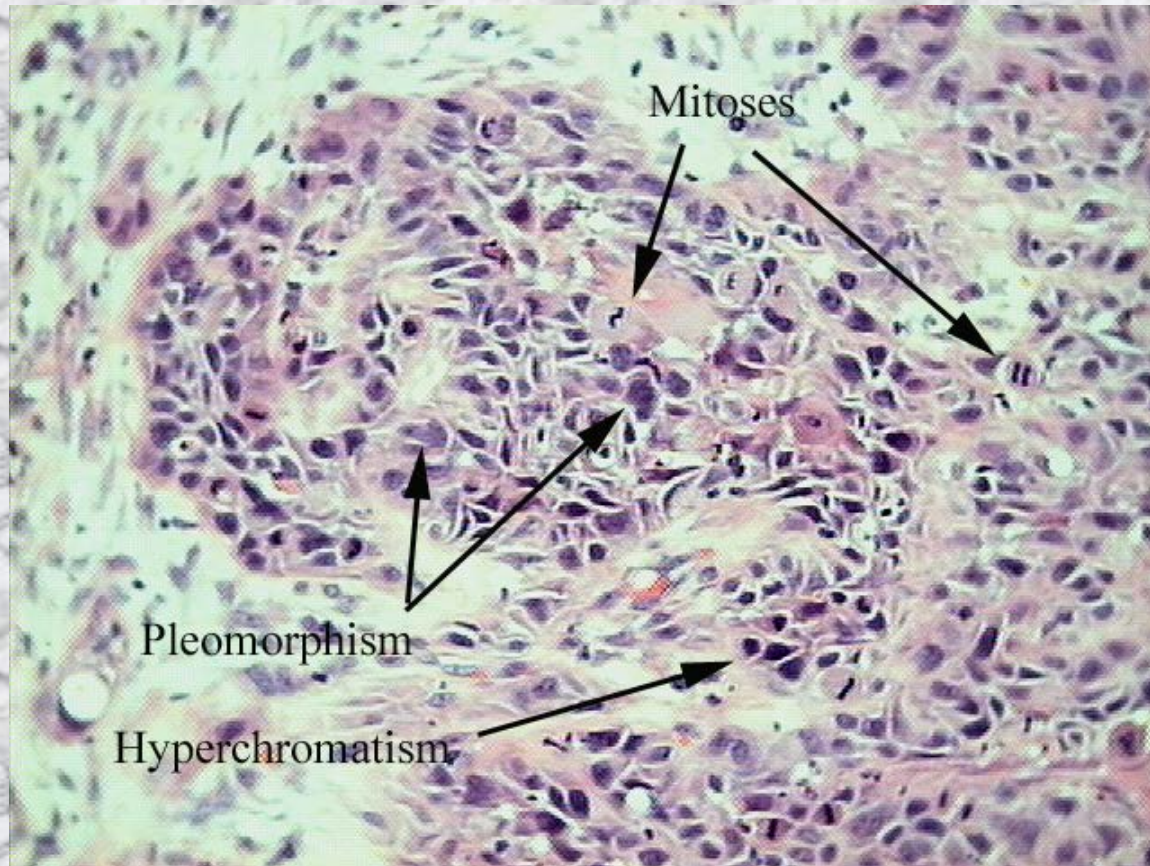
Cylindric Cell Papilloma



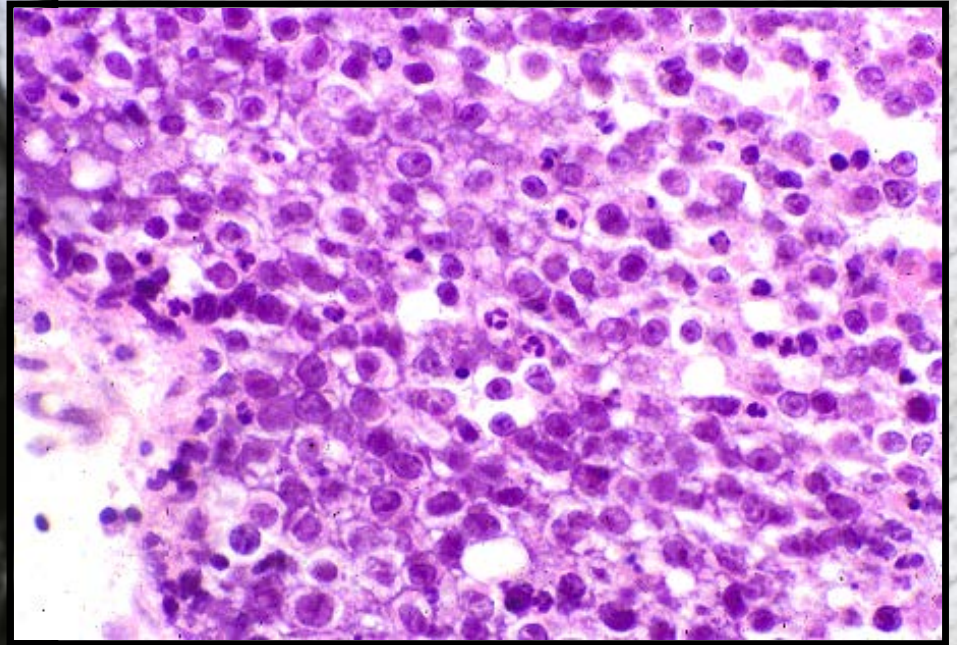
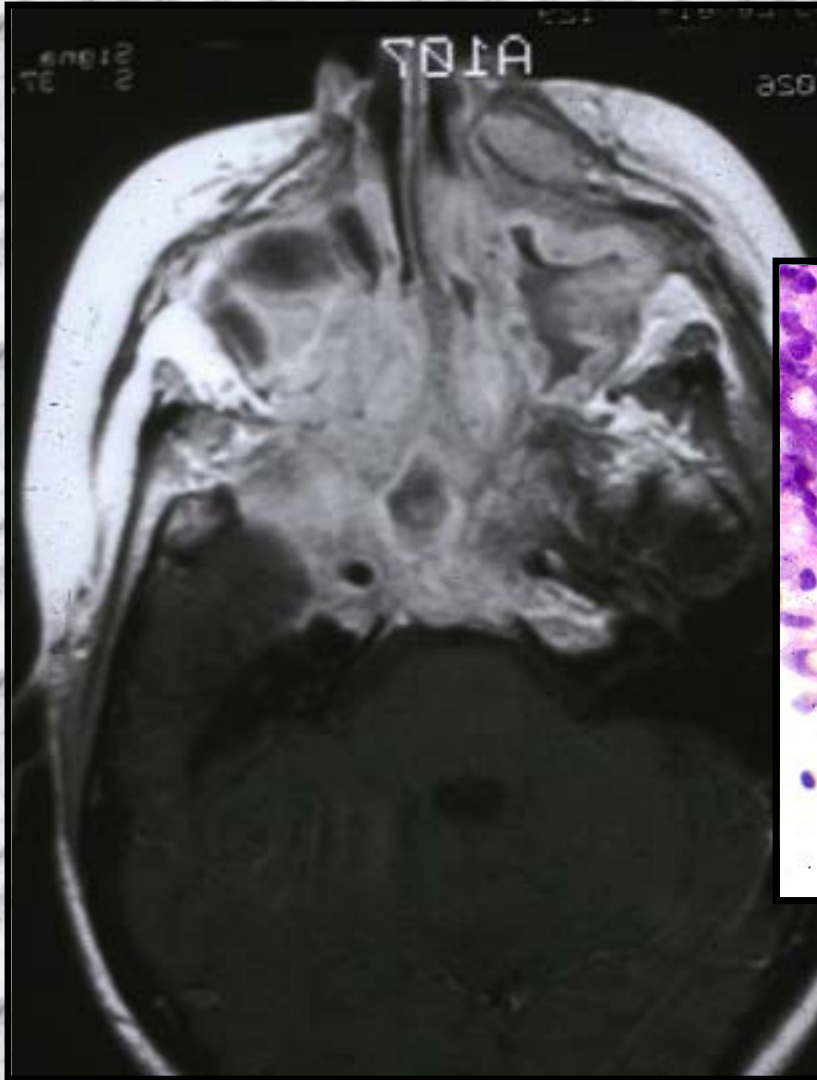
Antral Carcinoma

- Most are Squamous Cell Carcinomas
- Arise in antral roof
- Silent tumor
- Infraorbital paresthesia
- Histology
 - Keratinizing
 - Nonkeratinizing
 - SNUC
- Resection, Radiation Tx

SCCA of the Maxillary Sinus



Sinonasal Undifferentiated Carcinoma



Antral Sarcoma

- Malignant Fibrous Histiocytoma

